


**PATIENT**

Riley Overholster

**PRESENTING CLINICAL SIGNS**

History: New grade 4-5/6 systolic murmur. No cough, no exercise intolerance or open mouth breathing.

**SPECIES**

Feline

-Current medications: Meloxicam for arthritis.

-Abnormal PE/Chem/CBC/UA Results: Recent bloodwork NSF including T4.

**BREED**

DSH

**SEX**

Male Neutered

**ECHOCARDIOGRAM FINDINGS**

2D, m-mode, color flow and doppler imaging is available. The left ventricular wall is normal in dimension. There is a mildly hyperechoic endocardium consistent with fibrosis. Mild papillary muscle remodeling. The left atrium is normal in size. The right atrium is normal in size. No obvious MR is visualized; however, an intermittent leak is suspected. Trace TR. The right ventricle appears normal. The mitral valve can be seen causing a dynamic LVOTO on 2D imaging (see below). Blood flow through the RVOT is normal in velocity. Blood flow through the LVOT is mildly elevated with a dynamic profile. No cardiac tumors are seen. No pleural or pericardial effusion.

**AGE**

14.5 years

**CARDIAC CHART**
**WEIGHT**

11.3lbs

FELINE CARDIAC PARAMETERS	BODY WEIGHT (kg)	HR (BPM)	IVSd (cm) <small>(Moise, Pipers)</small>	LVIDd (cm) <small>(Moise, Pipers)</small>	LVWd (cm) <small>(Moise, Pipers)</small>	FS (%)	EF (%)
NORMAL PARAMETER	-----	150-240	0.35-0.55	<2 <small>(mean 1.5)</small>	3.5-0.55	35-67	80-100
PATIENT	5.13	NM	0.5	1.7	0.46	55	88
FELINE CARDIAC PARAMETERS	LA/AO <small>(Boon)</small>	LA/AO HEART BASE (Swe) <small>(Abbott)</small>	LA 2D short axis Base view (cm) <small>(Abbott)</small>		LVOT VEL <small>(m/s)</small>	RVOT VEL <small>(m/s)</small>	E max <small>(m/s)</small>
NORMAL	<1.5	<1.3	<1.2		<1.6	<1.3	<0.9
PATIENT	NM	1.2	1.2		2.5	1.1	NM
<i>*Note: All measurements based upon multi-modal images and methods. An average value is reported.</i> Adapted from June Boon, Veterinary Echocardiography, 1998 Abbott J & MacLean H JVIM 2006;20: 111-119, Moise et al. Am J Vet Res 47:1476, 1986. Pipers et al. Am J Vet Res 40:882, 1979.							

**INTERPRETED BY**

 Maggie Machen Lamy,  
 DVM DACVIM  
 (Cardiology)

**IMAGING PERFORMED BY**

Crystal Hill, RVT

**HOSPITAL NAME**

 Glanbrook Vet  
 Services

**REFERRING VET**

Dr. Weaver

**INTERPRETATION OF THE FINDINGS & FURTHER RECOMMENDATIONS**

Essentially normal cardiac structure and function. The murmur is due to an LVOT obstruction with secondary MR, which is secondary to tachycardia. The valve itself appears normal, and no LVH is seen making this likely a stress/tachycardia-induced phenomenon. That being said, this may be the first sign of early HOCM, and serial monitoring is advised. The left atrium is normal indicating low risk for complication. No additional issues are identified.

**INVOICE**

22221

**DATE**

11/30/21

In patients with persistent LVOT obstruction and development of hypertrophy, a beta blocker is often prescribed to lower heart rate and decrease the gradient. In this patient with a normal left atrium and no LVH, no medications are clearly indicated.



**PATIENT**

Riley Overholster

Anesthetic risk and/or steroid risk is currently low. Avoid heart rate stimulating drugs (atropine, glycopyrrolate) unless clinically necessary. Avoid vasodilators such as acepromazine as this can worsen obstruction. Judicious IV fluid rates are recommended to avoid fluid overload in this patient with diastolic dysfunction.

**SPECIES**

Feline

A recheck echocardiogram is recommended in 6-12 months, sooner if any clinical signs arise.

**BREED**

DSH

**SEX**

Male Neutered

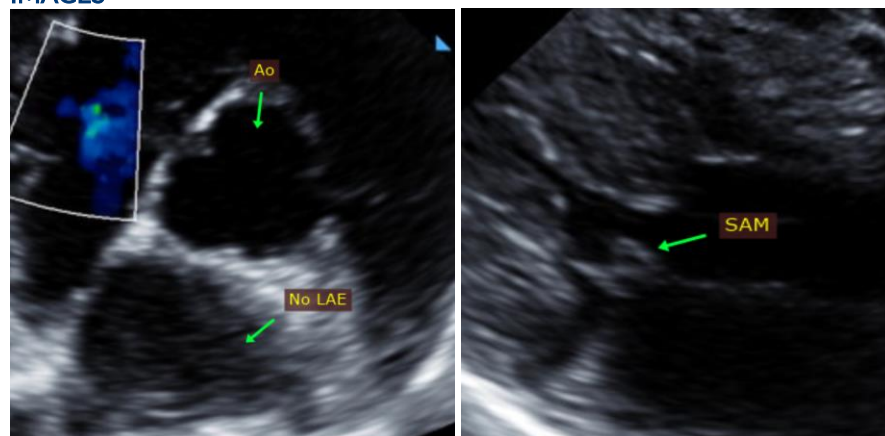
**AGE**

14.5 years

**WEIGHT**

11.3lbs

**IMAGES**



**INTERPRETED BY**

Maggie Machen Lamy,  
DVM DACVIM  
(Cardiology)

The information and recommendations provided are based on the images presented by the referring veterinarian. No evaluation can be communicated regarding pathology that was not visible in the image/video clips provided.

Thank you for this referral. This report was generated using transcription software, and minor dictation errors may be present. If the clinical or image interpretation does not parallel your findings or if I can be of any further assistance, please contact me.

**IMAGING PERFORMED BY**

Crystal Hill, RVT

**Maggie Machen Lamy, DVM**  
Diplomate of the American College of Veterinary Internal Medicine (Cardiology)  
info@sonopath.com

**HOSPITAL NAME**

Glanbrook Vet  
Services

**REFERRING VET**

Dr. Weaver

**INVOICE**

22221

**DATE**

11/30/21